

ORIGINAL ARTICLE

Tonic contractions of the tensor tympani muscle: a key to some non-specific middle ear symptoms? Hypothesis and data from temporal bone experiments

HANS WILHELM PAU¹, CHRISTOPH PUNKE¹, THORSTEN ZEHLICKE¹,
DIRK DRESSLER² & UWE SIEVERT¹

¹Klinik und Poliklinik für Hals-Nasen-Ohrenkrankheiten, Kopf- und Halschirurgie and ²Klinik und Poliklinik für Neurologie, Universität Rostock, Rostock, Germany

Abstract

Conclusions. The results of this study show that in clinical practice it will not be easy to diagnose tonic contractions of the tensor tympani muscle and only a combination of findings will be helpful. Based on these experimental results a clinical study will be started which should clarify the diagnostic relevance of indicators of tonic tensor muscle contractions. **Objectives.** There are indications from the literature and from personal experience that tonic contractions of the tensor tympani muscle may play a role in some ear symptoms, such as fullness, certain cases of tinnitus, slight hearing loss or Ménière's disease-like findings. In order to prove this theory we looked for indicators, either visual or functional, to help clinically diagnose the functional state of the muscle, particularly its tonic contraction. **Material and methods.** Experiments simulating tensor contractions were carried out on temporal bone specimens. Traction was applied either to the isolated muscle, to its tendon or to the malleus neck. Effects were observed either visually via an endoscope or by impedance audiometry using multiple-frequency tympanometry. **Results.** During simulated tensor traction the aspect of the tympanic membrane changed slightly, i.e. there was some inward movement of the umbo. However, such effects were only identifiable during the pulling action or by directly comparing the "contracted" and "relaxed" states. Tympanometry revealed a decrease in the peak amplitudes and a shift in the middle ear resonance towards higher frequencies during contractions.

Keywords: Fullness of the ear, middle ear resonance frequency, tinnitus impedance audiometry, tensor tympani muscle, tonic tensor contractions

Introduction

The function of the middle ear muscles is far from being fully understood [1,2]. This applies particularly to the tensor tympani muscle, in which contractions can be elicited much better by trigeminal nerve stimuli than by acoustic stimuli [3,4].

In the early "otosurgery" of the 19th century, dissection of the tensor tendon was a common procedure for a number of different indications [5]. Although such methods were later abandoned, more recently "tensotomy" has been advocated for selected cases of fullness of the middle ear, tinnitus or even Ménière's disease (MD) [6,7].

In some cases of transient hearing loss with abrupt onset, sometimes in combination with tinnitus and a

feeling of pressure and characterized by a quick and complete recovery, tonic contractions of the tensor tympani muscle have been suspected to be the underlying pathophysiological mechanism. Klockhoff [8,9], in the 1970s, was the first to describe a "tensor tympani syndrome", which seems to have been almost forgotten in the meantime. One of the reasons for this may be the difficulty of diagnosing tonic tensor contractions. Such tonic contractions should not be mistaken for myoclonic contractions, which are far more often the subject of publication [3,6,10–14]. It is much easier to make the latter diagnosis. In the recent literature, myoclonic contractions of the tensor tympani muscle, and also of the soft palate muscles, have been related to an

Correspondence: Hans Wilhelm Pau, Klinik und Poliklinik für Hals-Nasen-Ohrenheilkunde, Kopf- und Halschirurgie, Universität Rostock, Doberaner Strasse 137-9, 18057 Rostock, Germany. Tel: +49 381 494 8300. Fax: +49 381 494 8302. E-mail: hans-wilhelm.pau@med.uni-rostock.de

(Received 14 February 2005; accepted 12 May 2005)

ISSN 0001-6489 print/ISSN 1651-2551 online © 2005 Taylor & Francis
DOI: 10.1080/00016480510012408

objective form of tinnitus. This means that tinnitus caused by frequent muscle contractions can be recorded or even heard by the investigator. Symptoms range from some "fluttering sensations" to high-frequency tinnitus [10,11].

In the case of clonic tensor tympani contractions, symptoms are caused by inward-outward movements of the eardrum, whereas soft palate contractions present instead as smacking or clicking sensations typically caused by rapid openings and closings of the Eustachian tube by pathologic actions of the tensor and levator veli palatine muscles [15]. "Rhythmic" movements of the tympanic membrane may be detected otoscopically and on impedance audiometry the curve of the tympanogram may show a shivery, sawtooth pattern [9–12].

In this paper we deal with the question of tonic contractions. As well as adding some new thoughts to Klockhoff's theories, we particularly questioned whether a tonic contraction of the tensor, if present at all, can actually be registered once it has reached a steady-state phase and asked if it is possible to make a diagnosis of tonic tensor contraction in clinical practice. We tried to identify indicators of increased tensor muscle tone. For this purpose, the effects of tensor tension on the eardrum and ossicles were studied. In experiments on temporal bone preparations, tensor tympani contractions were imitated by directly pulling on the muscle or the neck of the malleus. Effects of tensor tension on the visual aspect of the eardrum and on impedance audiometry were recorded.

Material and methods

Experiments were carried out on five human temporal bones obtained from body donors (Institute of Anatomy, University of Rostock). After being obtained from the body at most 48 h post-mortem, the specimens were deep frozen. All tympanic membranes looked normal, but differed in terms of transparency.

Experiments were started 4 h after defrosting and temperature equilibration. During the experiments, dehydration was avoided by moistening the surface with a fine water spray at regular intervals. Specimen preparation was started by carefully removing the tegmen tympani without injuring the ossicular chain.

In two of the specimens, tension was applied via the muscle belly. For this purpose, the Eustachian tube was identified, together with the tensor tympani running parallel to it. The semicanalis tensoris tympani was opened and the muscle fibers were separated from their insertion on the bone as far as possible. Thus the muscle belly was widely detached, its tendon and adjacent muscle fibers remaining in

their bone canal next to the processus cochleariformis.

A 5-0 surgical suture (Resolon; Resorba, Germany) was firmly tied around the muscle, allowing simulation of muscular contractions by means of the application of tension forces in the direction of the muscle fibers (Figures 1 and 2a). In two other specimens, tensor activity was simulated by applying tension to its tendon. After carefully opening the tegmen tympani, the tensor tendon was identified and exposed. A firm ligature was tied to the middle portion of the tendon, i.e. between its insertion into the malleus and the lenticular process (Figure 2b).

In the remaining temporal bone the traction force was applied directly to the malleus. The malleus neck was perforated with a CO₂ laser beam (laser scanning system similar to that used for stapes surgery [16]; 20 W; 0.3-mm diameter; 10 shots) next to the insertion of the tensor tendon (Figure 2c). A 5-0 suture was passed through the malleus neck, via which tension could be applied directly to the malleus parallel to the direction of the tensor tendon. In this experiment we interrupted the tensor tendon and simulated its function by pulling the suture threads (Figure 2c).

In each experiment we connected the suture thread via a deflection pulley (Figure 1) to a very light small bag in which different weights could be placed. Starting with a load of 5 g, the tension was gradually increased in 5-g steps up to 35 g. The effects of simulated tensor contractions on the tympanic membranes were recorded with a digital

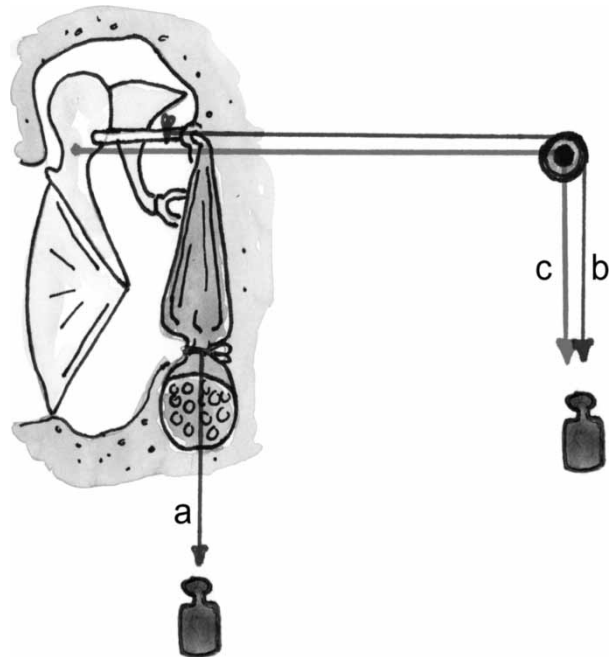


Figure 1. Experimental set-up for applying traction to the (a) muscle, (b) tendon and (c) malleus.

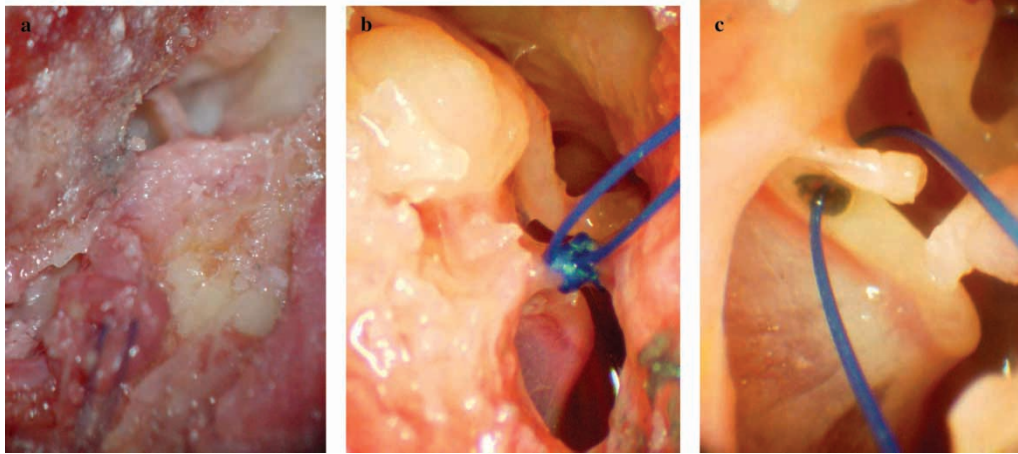


Figure 2. (a) The tensor muscle is separated from its bony canal. A surgical suture (two blue threads visible) is tied to the muscle belly. (b) A suture is fixed to the tendon of the tensor tympani muscle. (c) The malleus neck is perforated and a suture is passed through the perforation.

video camera attached to a 0° rod lens endoscope of 3.5-mm diameter (Storz, Germany). Subsequently, a plug for impedance audiometry was inserted into the external ear canal.

Multiple-frequency tympanometry was performed using a middle ear analyzer (TymStar Version 2; Grason Stadler, USA). Firstly, a standard tympanogram was recorded with a probe tone of 226 Hz. The machine automatically calculates the resonance frequencies by comparing the impedance and phase measured at the “start pressure” to those at peak pressures of the normal tympanogram (for 226 Hz) after a sweep across the frequency range. The tympanogram at the resonance frequency was also recorded. As the tension on the malleus was increased, the following were recorded: “normal” tympanograms; resonance frequencies; and tympanograms at the resonance frequency. The data initially stored in the middle ear analyzer were edited by printing.

Results

General remarks

Applying traction to the muscle/tendon/malleus can only very roughly imitate actual tensor actions. By pulling the muscle itself not all of the forces reach the malleus, as remaining muscle adhesions on the bony sheath absorb some energy. This also applies to our second experiment. Although the suture could easily be tied to the tendon, again this did not prove to be a definitive point for power application. As the tension was applied to a point somewhere in the middle of the tendon, it can be assumed that even the “posterior part of the tendon” (from the knot to the processus cochleariformis) might have absorbed some energy.

We finally considered the direct application of tension to the bone (malleus), the best simulation of tensor action, although even this experiment could only roughly copy the situation found in nature. The dilemma represented by such analogies was taken into account by the authors and only tendencies are presented.

Endoscopy

On video clips, filmed through the endoscope, the effect of simulated tensor traction could be observed: during the dynamic phase of traction there was some inward movement of the manubrium mallei and umbo. However, once the steady-state phase was reached, no difference or almost no difference in the aspect of the tympanic membrane could be observed. This is illustrated by Figure 3, taken from a video clip, which demonstrates the aspect of an eardrum without and with tensor traction. Only from the extra lines drawn for clarification can differences between the two pictures be seen. The manubrium mallei actually looks a little “shorter” and more “horizontal” during simulated tensor contractions, but even in direct comparison to the “relaxed” state it is hard to detect a difference. However, in the video clip, or if Figure 3b is viewed directly after Figure 3a, the inward movement of the malleus/umbo is evident.

Impedance audiometry

In each of the five specimens the external ear canal could be correctly tightened using a plug for impedance audiometry, so that tympanograms could be recorded and middle ear analysis could be performed. However, there were large differences in the amplitudes of the peaks among the five

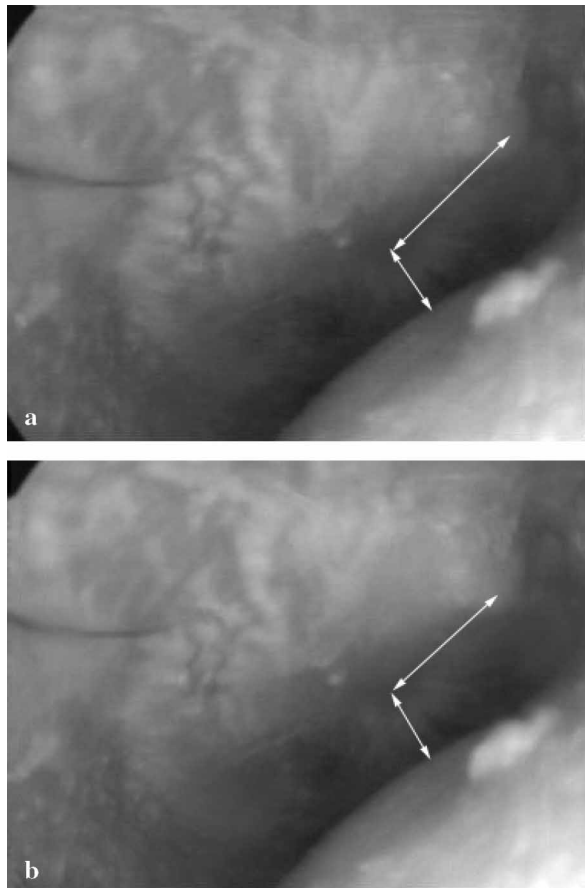


Figure 3. Aspect of the tympanic membrane with and without simulated contraction of the tensor muscle. In (b) the line along the malleus handle (*upper arrow*) is a little shorter than that in (a), whereas the lower arrow (perpendicular to the malleus) is a little longer, indicating some inward movement of the malleus during the muscular contraction.

temporal bones examined. This can be related to the condition of the individual temporal bone: pre-existing scars, thickness of the membranes, state of the ossicular chain, width of the experimental opening, degree of exposure, etc. The state of the tensor tendon in extreme situations (either fixed by a suture or completely interrupted) also plays a significant role. We therefore decided to include the curves for each individual temporal bone in diagrams (Figures 4–6) rather than to calculate mean values and perform statistical evaluations.

Figure 4 shows the effect of increasing traction force (5–35 g) on the amplitude of the compliance. Acoustic resistance was expressed by volume equivalents (cubic centimeters). In each temporal bone, an increase in traction caused a decrease in the compliance curves, regardless of the condition of the individual temporal bone and the preparation performed (traction on the muscle/tendon/malleus). However, the extent of the effects differed among the specimens and between the methods used.

Figure 5 presents the results of increasing traction on the resonance frequencies in each individual temporal bone. Overall there was an increase in the resonance frequency, the extent of which again depended on the status of the specimens and the application of force.

From Figure 6 it can be seen that there was no major shift in the tympanogram with regard to pressure: the peaks of the curves occurred in a 20-daPa range around zero.

The trend in Figures 4–6 was so evident and in accordance with basic physics that the small number of temporal bones studied would seem to be sufficient. As in our opinion the direct application of power towards the malleus neck gave the best simulation of tensor contractions, characteristic tympanograms and results from middle ear analysis for this specific temporal bone specimen are shown in Figure 7.

Discussion

We want to emphasize that the aim of this paper was not to quantify small movements of the eardrum or ossicles during the dynamic phase of tensor contraction or relaxation. Instead, we tried to find indicators which may help to determine whether the muscle was contracted or not. For each given steady state of “contraction” (i.e. different loads on the muscle/

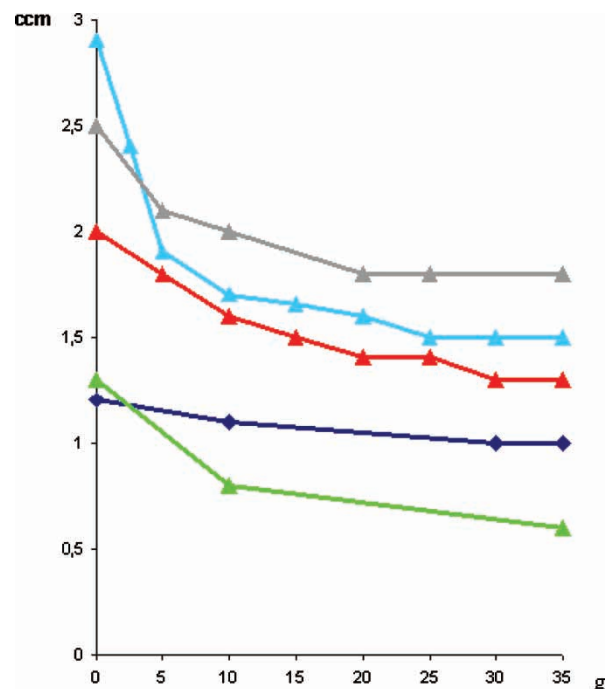


Figure 4. Peak amplitude of the tympanogram at 226 Hz for the 5 temporal bones plotted against increasing traction force (5–35 g). Dark blue and green curves: traction applied to the tensor muscle; grey and red curves: traction applied to the tendon; light blue curve: traction applied to the malleus neck.

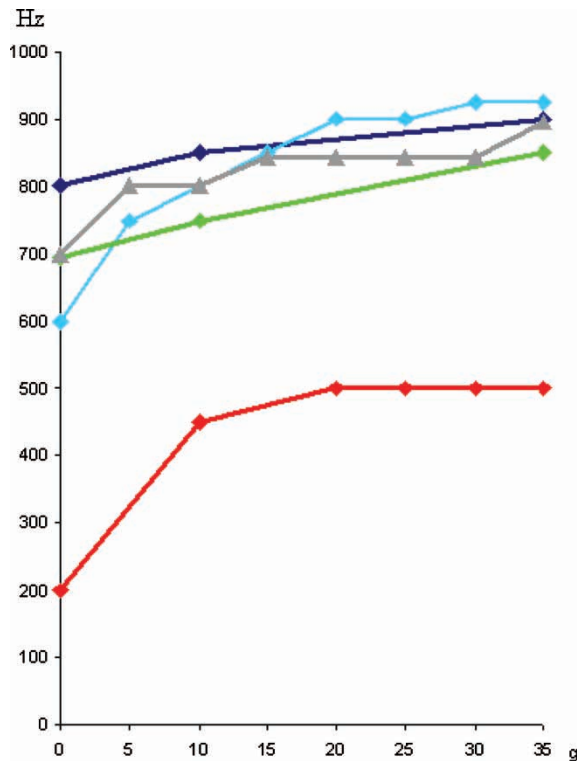


Figure 5. Resonance frequencies of the five temporal bones with increasing traction simulating tonic tensor contraction. Key as in Figure 4.

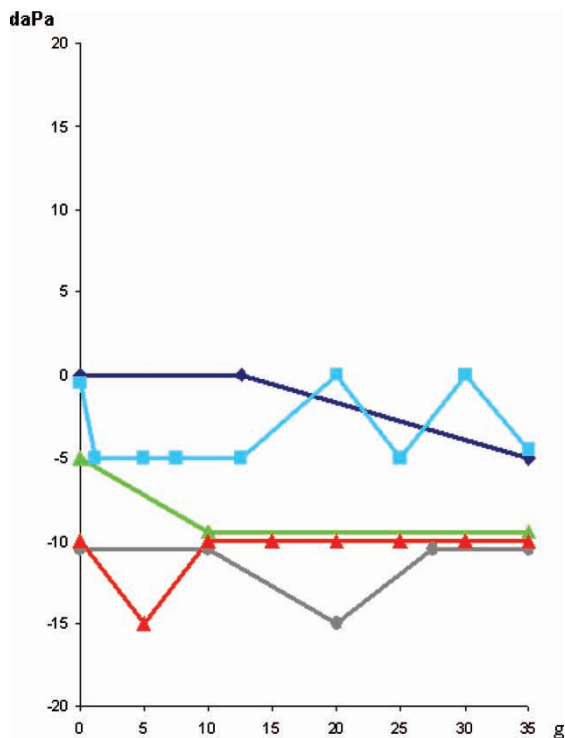


Figure 6. Pressure at the peak of the tympanogram with increasing traction force. Key as in Figure 4.

tendon/malleus in our experiments) we looked for definitive parameters, either from the visual aspect or from impedance audiometry. The intention was to be able to judge whether in a given patient the tensor was contracted or not. Unfortunately the parameters we found proved to be rather feeble: there were almost no visual changes, which were only recognizable during acute contraction, and only small differences in the amplitude of tympanograms or slight shifts in the resonance frequencies.

Given the general nature of our conclusion, we did not consider it necessary to improve the accuracy of the absolute data or to increase the number of temporal bones. Of course the visual recordings might have been improved by using more sophisticated techniques, such as the interference moiré technique developed by Van Unge et al. [16], which would surely have given more precise data about small changes in the position of the eardrum. The same applies to the impedance measurements: the absolute values of such data are greatly influenced by many physical parameters. As we had to work on opened temporal bones, these absolute values surely differ a lot from those obtained in vivo. However, in our experiments there was a clear tendency towards a change in the aspect of the tympanic membrane with regard to the two conditions contracted or not contracted. Furthermore, the effects are in accordance with the physical theory. Being fully aware of the experimental limitations, we feel that a combination of indicators—slightly retracted umbo (malleus), rather low amplitude of the tympanogram and raised resonance frequency—may reveal tensor contractions. Klockhoff [8,9] saw some “lability” in the tympanometric recordings in his patients, which should also be taken into consideration (repeated impedance recordings). The corresponding data from the opposite ear must be taken into account, as well as data from the same ear registered at intervals.

There are several theories regarding the function of the tensor tympani muscle: (i) prevention of jingling of the ossicles at high sound pressure levels [1,2,17]; (ii) increasing the resonance frequency of the middle ear to protect the inner ear from high sound pressure levels [18]; and (iii) allowing better discrimination of high-pitched sounds while listening (an outdated theory). The tensor tympani muscle seems to be involved in the control of middle ear pressure, in Eustachian tube function or even in secretion of the middle ear mucosa [19–21]. According to Hüttenbrink’s theory [1,2], the most important function of the middle ear muscles is to maintain the joints between the ossicles in a functioning condition.

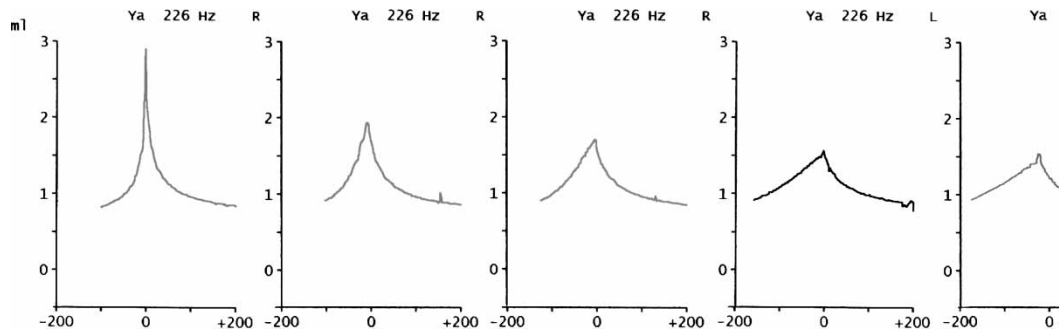


Figure 7. Changes in the tympanogram at 226 Hz in an individual temporal bone with increasing traction force simulating tonic tensor contraction.

The tensor tympani muscle is innervated by the mandibular branch of the trigeminal nerve, similar to the situation with the masticatory muscles. It is well known that in the latter group of muscles the tonus can be raised significantly, e.g. by stress factors. We hypothesize that some cases of ear fullness, tinnitus or even MD symptoms might be explained by tonic contractions of the tensor tympani muscle. Such ideas have been published before by Klockhoff [3,8,9], who described a “tensor tympani phenomenon” or even a “tensor tympani syndrome” 30 years ago, consisting of fullness of the ear (sometimes otalgic), tinnitus (sometimes pulsating), dysacusis (various acoustic sensations), tension headache (frontal and occipital) and occasionally vertigo. Klockhoff claimed that increased psychic tension due to mental stress was the most important factor. While dizziness and dysequilibrium were considered to be of central origin, fullness, tinnitus and dysacusis should be directly related to the muscle activity of the tensor tympani. In such patients Klockhoff saw an “impedance lability” of the middle ear system, which he considered a pathognomonic sign. His term “dysacusis” included sensations such as murmurs, clicks, tickling sensations, etc., whereas he disagreed that abnormal significant hearing loss “in the conventional sense” might occur. In contrast, we consider that even a slight bone conduction hearing loss may be due to tensor dysfunction. In clinical practice we observed a type of “sudden” hearing loss, mostly in the lower frequencies, in which the patient reports a very rapid onset of symptoms. Characteristically, these may completely recover after hours or days, again within only a short period of time.

In one patient we saw 4 episodes of low-frequency hearing loss (25 dB) within 2 weeks, combined with a feeling of fullness of the ear. Each episode lasted for ≈ 1 day before a return to normality, with the patient reporting that the ear had “slowly opened again” (Figure 8).

Most people experience very short “attacks” of hearing loss every now and then, mostly accompanied by some tinnitus, which vanish within a matter of seconds. We speculate whether some of these attacks, even when audiograms suggest sensorineural hearing loss, may be interpreted as “tensor-induced”. The audiograms for the cases mentioned above comply with some of those in the literature, in which hearing loss was actually related to tensor contractions. Unfortunately, those audiograms did not explicitly differentiate between air and bone conduction [22].

We know that traction of the tensor tympani muscle increases the stiffness of the middle ear system, which has a significant impact on bone conduction. As a parameter of inner ear function, bone conduction has two components: (i) the direct transmission of bone vibrations into the inner ear fluids; and (ii) the “osteo-tympanal” component [23]. The latter component is based on the fact that vibrations of the bone simultaneously cause vibrations of the ossicular chain, which consequently transfer the energy, as in air conduction, to the inner ear via the stapes footplate. Stiffening the middle ear system, which is comparable to the Gellé test with the tuning fork and the Politzer balloon, causes deterioration of the osteo-tympanal component of bone conduction for lower frequencies. Thus, measurements of bone conduction as an indicator of inner ear function may mimic sensorineural hearing loss.

Klockhoff claimed that the symptoms (particularly dizziness and fullness) had something in common with MD, from which however it should be distinguished [8]. In contrast, Franz et al. [7] discussed the very close correlation between tensor activity and MD. By sectioning the muscle or its tendon they could reduce the frequency and intensity of vertigo and tinnitus in such cases.

So far we have only discussed a potential role of the tensor tympani muscle in cases of fullness of the ear, in selected cases of tinnitus and even in hearing loss. However, it seems hard to prove such theories,

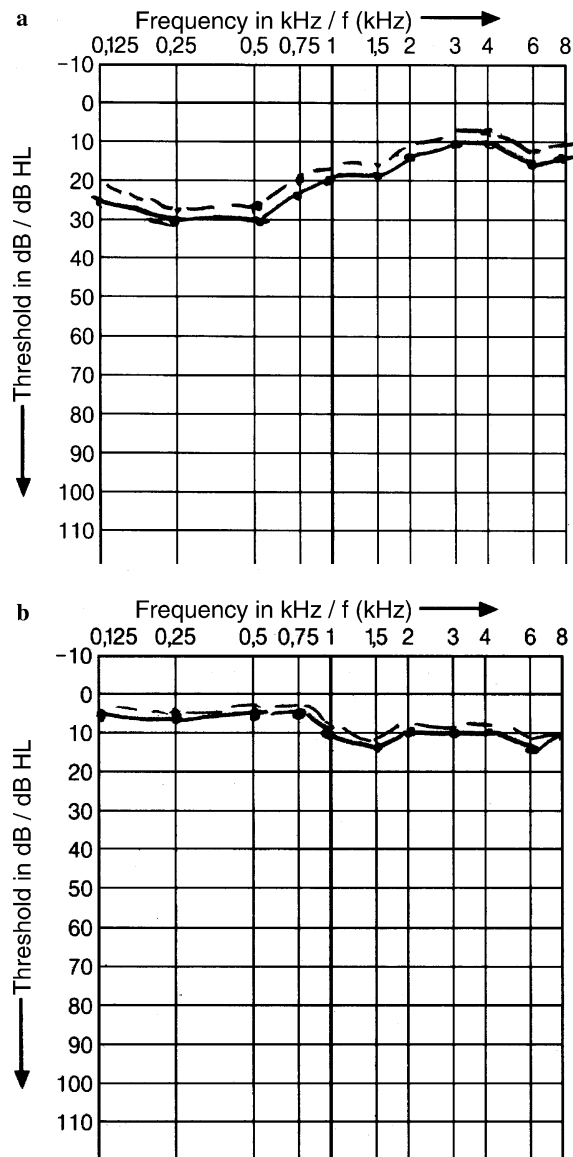


Figure 8. Audiograms obtained in a patient (a) during "sudden hearing loss" and (b) 1 day later. Such events were observed four times within a 2-week period.

as there are no striking indicators of a contracted muscle, either visually or using common clinical tests. Even Klockhoff's "abnormal impedance lability" of the ear does not seem to be a very specific sign. In contrast, the diagnosis of another tensor dysfunction in the form of myoclonic contractions is much easier, as the rapid sequence of contraction and relaxation often causes some "fluttering" feeling or even tinnitus in the ear involved. Impedance audiometry recordings characteristically show very unsteady curve progressions ("sawteeth"). In our experiments we simulated tonic contractions and found only slight changes in the visual aspect of the eardrum or in the impedance audiometry findings. These changes can almost only be detected by comparing the state with and without contraction.

There are some individuals who can voluntarily contract their middle ear muscles, probably mainly the tensor. In these individuals the inward-outward movement of the umbo or malleus handle can be visualized easily. However, in the steady state it is difficult to judge whether there is contraction or relaxation, as even in normal ears the aspect of the tympanic membrane varies over a wide range. Of course during contraction the malleus handle looks a little shortened and more horizontal due to its inward torsion. Its aspect may resemble an ear with negative middle ear pressure, but it may also represent the normal aspect for the individual patient. The same applies to the tympanogram. In contrast to cases with negative middle ear pressures the tympanogram looks "normal". In our experiments the peak of the tympanogram was at 0 daPa (within a 15-daPa range), no matter how hard the traction on the tensor or malleus neck. Characteristic changes were only found in the amplitudes of the tympanograms and in the resonance frequency of the middle ear system.

Conclusions

To prove whether or not tensor contractions may be considered a cause of "pressure in the ear", certain types of tinnitus or even MD-like symptoms, such patients should be checked for the combination of slightly retracted eardrums, decreased amplitude of the tympanogram, elevated resonance frequency and of course "abnormal impedance lability" according to Klockhoff. As it is hard to evaluate the absolute parameters, the affected ear should be compared to the contralateral one or to the same ear during symptom-free periods. To date we only have some vague hints that tonic contractions of the tensor muscle may play a role in individual patients. Based on our experimental findings a more detailed study of subsequent patients with the symptoms mentioned above will be started.

References

- [1] Hüttenbrink KB. The mechanics of the middle-ear at static air pressures. *Acta Otolaryngol Suppl* (Stockh) 1988;451:1-35.
- [2] Hüttenbrink KB. Die Bewegung der Gehörknöchelchen durch die Mittelohrmuskel-Kontraktion. *Laryngorhinootologie* 1989;68:614-21.
- [3] Klockhoff I. Middle ear muscle reflexes in man. *Acta Otolaryngol Suppl* (Stockh) 1961;164:1-92.
- [4] Raachfuss A, Hiller E, Leitner H, Wöllmer W. Reaktion des M.tensor tympani—ausgelöst durch nasal applizierte Trigeminalreizstoffe. *Laryngorhinootologie* 1987;66:131-2.
- [5] Kessel J. Über die vordere Tenotomie. *Arch Ohrenheilkd* 1891;31:131-43.

- [6] Badia L, Parikh A, Brookers GB. Management of middle ear myoclonus. *J Laryngol Otol* 1994;108:380–2.
- [7] Franz P, Hamzavi JS, Schneider B, Ehrenberger K. Do middle ear muscles trigger attacks of Ménière's disease? *Acta Otolaryngol* 2003;123:133–7.
- [8] Klockhoff I. Diagnosis of Menière's disease. *Arch Otorhinolaryngol* 1976;212:209–14.
- [9] Klockhoff I. Impedance fluctuation and a "tensor tympani syndrome". In: Penha RL, Rizarro W, editors. *Proc Fourth Int Symp Acoustic Impedance Measurement*. Lisbon: Universidad Nova de Lisboa; 1981. p. 69–76.
- [10] Bento RF, Sanchez TG, Miniti A, Tedesco-Marchesi A. Continuous, high-frequency objective tinnitus caused by middle ear myoclonus. *Ear Nose Throat J* 1998;77:814–8.
- [11] Abdul-Baqi KJ. Objective high-frequency tinnitus of middle ear myoclonus. *J Laryngol Otol* 2004;118:231–3.
- [12] Brosch S, Riechelmann H, Johannsen HS. Myoklonus des Mittelohres. *HNO* 2003;51:421–3.
- [13] Oliveira CA, Negreiros J, Cavalcante IC, Bahmad F, Venosa AR. Palatal and middle-ear myoclonus; a cause for objective tinnitus. *Int Tinnitus J* 2003;9:37–41.
- [14] Gelb H, Gelb ML, Wagner ML. The relationship of tinnitus to craniocervical mandibular disorders. *Cranio* 1997;15: 136–43.
- [15] Schwab B, Lenarz T. Myoclonus. *HNO* 1998;46:885–6.
- [16] Von Unge M, Decraemer WF, Bagger-Sjoberg D, Dirckx JJ. Displacement of the gerbil tympanic membrane under static pressure variations measured with a real-time differential moiré interferometer. *Hear Res* 1993;70:229–42.
- [17] Von Békésy G. *Experiments in hearing*. Huntington, NY: Robert E Krieger; 1980.
- [18] Lehnhardt E. Weitere Untersuchungen über den Einfluß der Binnenohrmuskeltätigkeit auf die Empfindlichkeit des Ohres. *Acta Otolaryngol (Stockh)* 1969;52:438–44.
- [19] Elner A. Normal gas exchange in the human ear. *Ann Otol Rhinol Laryngol Suppl* 1976;85:161–4.
- [20] Eden AR. Neural connections between the middle ear, eustachian tube and brain. Implications for the reflex control of middle ear aeration. *Ann Otol Rhinol Laryngol* 1981;90: 566–9.
- [21] Ingelstedt S, Johnson B. Mechanisms of the gas exchange in the normal human middle ear. *Acta Otolaryngol Suppl (Stockh)* 1967;224:452–66.
- [22] Rock E. Objective tinnitus and the tensor tympani muscle. *Int Tinnitus J* 1995;1:30–7.
- [23] Lehnhardt E, Laszig R. *Praxis der Audiometrie*. Stuttgart, Germany: Thieme; 2000.

Copyright of *Acta Oto-Laryngologica* is the property of Taylor & Francis Ltd and its content may not be copied or emailed to multiple sites or posted to a listserv without the copyright holder's express written permission. However, users may print, download, or email articles for individual use.